Chaya Newfield
Ambulatory Medicine Site Evaluation

History and Physical

Identifying Data:

Full Name: ER
Address: Brooklyn, NY
Date of Birth: **/**/2000
Date and Time: 7/1/2021 3:00 PM
Location: Statcare Urgent Care, Brooklyn, NY
Sex: Male
Age: 20
Race: Latino
Nationality: USA
Religion: unknown
Marital Status: single
Source of Information: Self
Reliability: Reliable
Source of Referral: Self

Chief Complaint: Pain in shoulder x1 week

HPI
20 y/o male presents for left arm pain x1 week. States that the pain has been on and off every few hours. Pain initially began at the left shoulder extending down to left upper arm. The pain is currently radiating down to the left elbow. Pain is exacerbated with extension of the left arm. Pt has tried Aspirin and Ibuprofen with little to no relief. Patient states he felt “tingling” in the arm when the pain began.
Patient also notes "piercing" chest pain x 1 day. Heart palpitation before bedtime for the past few days. Also c/o neck pain x3 days. Admits recent asthma exacerbation last night, patient took one tab prednisone prescribed by PCP for asthma flare ups.
Pt admits to trying Cocaine at age 15, takes Percocet, Oxycodone for recreational purposes. Denies numbness, fever, chills, cough, SOB, recent trauma/fall. Denies known heart murmur, FHx of heart diseases.

Past Medical History:
Asthma (uses inhaler PRN)

Immunizations – All vaccinations up to date.

Past Surgical History: No significant surgical hx.

Medications: Albuterol Sulfate (PRN for asthma)
Percocet (oxycodone-acetaminophen) (not prescribed by medical professional)

Allergies:
fish – Hives
Peanut- Hives

Family History:
Mother – 50, alive and well
Father – 55, alive and well, essential HTN
Paternal grandmother, deceased at 70, hx of essential HTN

Social History:
Pt lives with his parents in an apartment in Brooklyn, NY.
Habits – Admits cigarette smoking and marijauna smoking, admits to routine recreational Percocet use, occasional social drinking once a month.
Travel – Denies any recent travel or sick contacts.
Diet – Eats a normal diet that is high in proteins, with moderate fats and sugars.
Exercise – Denies exercising or other aerobic activity.

Review of Systems:
General –Denies recent weight loss, fever and chills, generalized weakness/fatigue, or night sweats.
Skin, hair, nails – Denies changes in texture, excessive dryness or sweating, discolorations, pigmentations, moles/rashes, pruritus or changes in hair distribution.
Head – Denies head trauma.
Eyes – Denies excessive lacrimation, pruritus, other visual disturbances, or photophobia.
Ears – Denies any changes in hearing.
Nose/sinuses – Denies obstruction, discharge or epistaxis.
Mouth/throat –Denies bleeding gums, sore tongue, sore throat, mouth ulcers.
Neck – Denies localized swelling/lumps or stiffness/decreased range of motion
Pulmonary system –Denies wheezing, dyspnea, dyspnea on exertion
Cardiovascular system – **Admits recent chest pain, admits palpitations at night,** denies syncope, dyspnea on exertion, orthopnea
Gastrointestinal system – Denies abdominal pain, constipation, diarrhea, vomiting
Genitourinary system – Denies urinary frequency or urgency, oliguria, polyuria, dysuria.
Nervous – Denies seizures, headache, loss of consciousness, sensory disturbances, ataxia, loss of strength, change in cognition / mental status / memory, or weakness.
Musculoskeletal system – **Admits left arm muscle pain radiating down to left arm**, denies painful joints
Hematological system – Denies anemia, easy bruising or bleeding, lymph node enlargement, blood transfusions.
Endocrine system – Denies polyuria, polydipsia, polyphagia, heat or cold intolerance, excessive

sweating, or goiter

Physical

Vital Signs:
R: 16, unlabored P: 76, regular
T: 98.2 degrees F (oral)
Height: 5 ft 11inches Weight: 260 lbs.
BMI: 36.26
Pain scale: 2/10

General: Well-appearing, well-nourished, in no acute distress
Skin: Warm and moist, no suspicious lesions
Hair: Moderate quantity, even distribution, smooth texture.
Head: Normocephalic, atraumatic, nontender to palpation.
Eyes: Symmetrical OU, No evidence of strabismus, exophthalmos, or ptosis. Sclera is white, conjunctiva pink, and clear.
Ears: Symmetrical and normal size. No evidence of lesions, masses, or trauma to external ears.
Nose: Nasal mucosa is moist. Symmetrical, no obvious masses, lesions, deformities, trauma.
Mouth and Pharynx:
Pharynx is pink and moist. Uvula pink, no erythema, lesions,mLips pink and moist without cyanosis or lesions.
Lungs: CTAB, no audible wheezing, rhonchi, or stridor.
Heart: Normal heart rate. S1 and S2 noted.
Abdomen: Soft, nontender, no masses palpable
Extremities: **Pain provoked with extension of left arm** No evidence of clubbing, cyanosis or edema, full ROM, no asymmetric weakness

DDX:
Cardiac:

Angina, NSTEMI -- The patient is complaining of chest pain and L arm pain, and therefore should be evaluated for a cardiac cause of these symptoms.

Nervous:

Brachial plexus injury -- The patient noted a “tingling” sensation with symptom onset, which may indicate the brachial plexus nerves having been stretched or injured. Although he does not note trauma to the area, it may have been a minor event that is having residual effects.

Musculoskeletal:

Cervical disc herniation -- The patient notes neck pain x3 days and left arm pain.
Ligament sprain, Muscle strain -- The patient notes left arm pain that comes and goes. It is possible that the symptoms are worse after excessive use of the arm.

Imaging: EKG in office

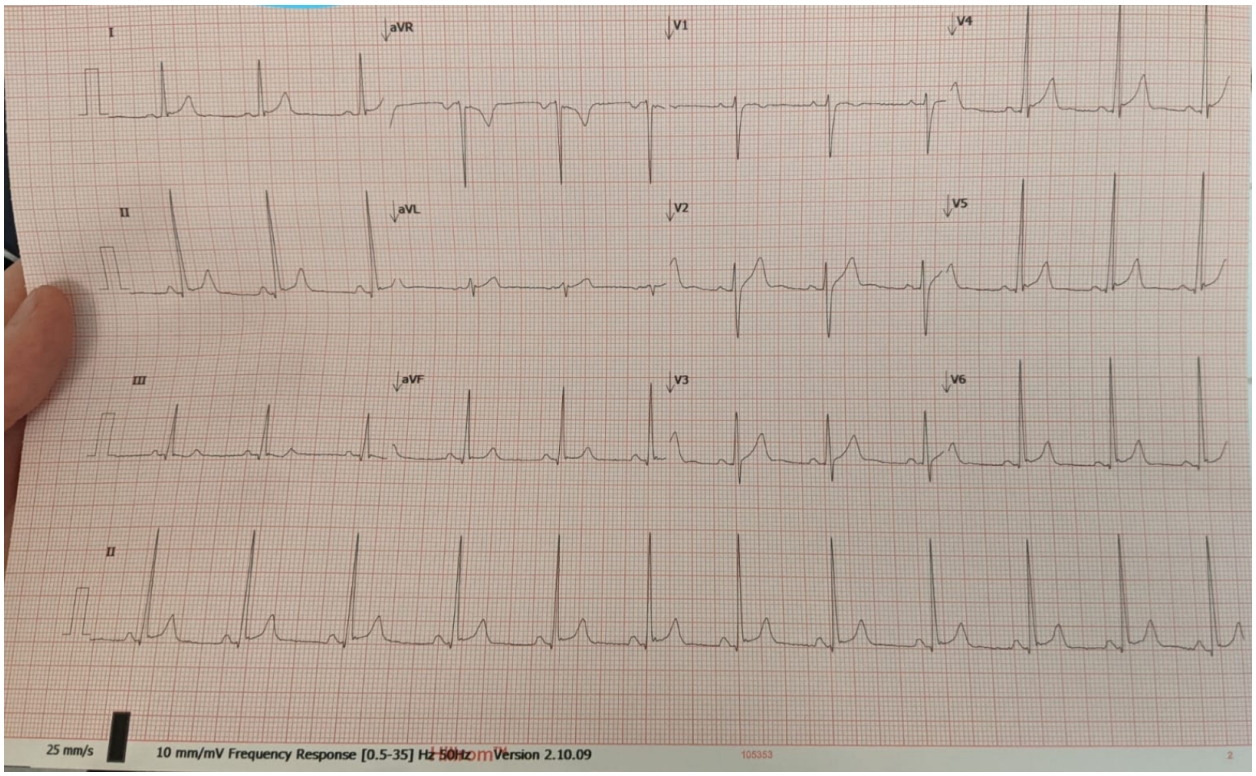

Assessment:
ER is a twenty-year-old male who is a current smoker with hx of recreational percocet use presenting with intermittent left arm pain radiating down left arm x1 week, neck pain x3 days, chest pain x1 day. EKG shows sinus rhythm with borderline anterior lead elevations. Patient's vital signs are currently stable and the patient is in no acute distress.

Plan:
Cardiac: The EKG report shows borderline elevations in anterior leads. The patient does not have a significant family history of MI, and his symptoms are more likely attributed to a musculoskeletal origin. However, in order to fully rule out a cardiac issue, the patient should be given a referral for cardiology where he may be placed on a holter monitor or undergo a stress test for further evaluation.

Musculoskeletal: Patient should be given a referral for a cervical x-ray to evaluate for cervical spinal disc herniation. He should be instructed to continue symptomatic care with heat/ice packs, OTC pain medication, and activity modification to avoid painful movements until the pain has subsided. If the pain continues to recur, the patient may benefit from referral to physical therapy.